

TRANSCUTANEOUS PACING EMMCO WEST ALS GUIDELINE

Criteria:

- A.** All patients with symptomatic bradycardia, without evidence of trauma, who:
1. Have high degree A-V block (second degree, type II, or third degree); or
 2. Are refractory after administration of atropine 1.0 mg; or
 3. Do not have patent IV access.
 4. Patients who deteriorate from a perfusing rhythm to bradycardia in the presence of the ALS practitioner (witnessed).

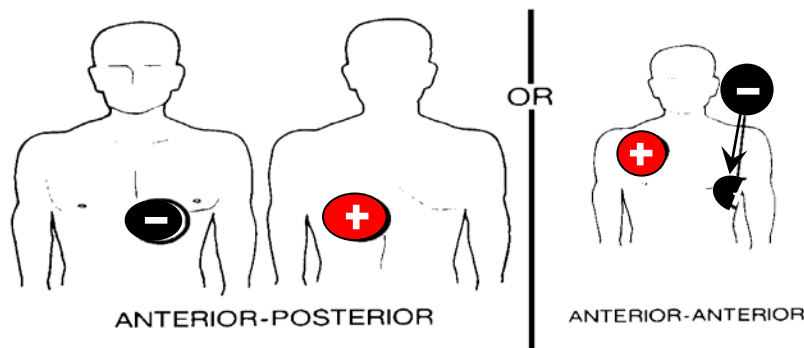
Exclusion Criteria:

- A.** Asystole in cardiac arrest that is not related to a witnessed deterioration from a perfusing rhythm to a bradycardiac cardiac arrest.
- B.** Asystole in cardiac arrest of traumatic etiology.

Procedure:

A. All Patients: ¹

1. Initiate cardiac monitor.
2. Determine that patient meets established criteria for transcutaneous pacing.
3. Patient Teaching: Explain procedure to patient and, if appropriate, to family. Include explanation of possible discomfort and use of deep breathing or other relaxation techniques as well as sedation, as needed.
4. Connect pacing cable to PACE connector at "Monitor" side of cardiac monitor/defibrillator.
5. Connect QUIK-PACE electrodes to pacing cables, which are color coded *Black* and *Red*.
6. Attach pacing electrodes to patient:
 - a. Apply electrodes to clean, dry skin. Clip, *do not shave* excess hair.
 - b. Anterior-posterior positioning is preferred:
 - 1) Black = anterior; Red = posterior. Place the anterior electrode (negative) on left anterior chest halfway between the xiphoid process and the left nipple with the upper edge of the electrode below the nipple line. Place the posterior electrode (positive) on the left posterior chest, beneath the scapula and lateral to the spine.
 - c. Anterior-anterior placement should only be used if A-P placement is contraindicated. Place the Black (negative) electrode on the left chest, mid-axillary, over the fourth intercostal space. Place the red (positive) electrode on the anterior right chest, subclavicular area. (*See diagram*)



7. Press "Pace". If needed, adjust ECG size so that each QRS complex that is sensed is marked by a "□" symbol on the screen. The recorder paper will mark each pacer spike with a "□" in the lower margin.
8. Set pacing rate using "Rate" selector. In the absence of Medical Command, set a rate of 80 bpm.
9. Activate pacing by using "Start/Stop" selector.
10. Adjust the pacing energy:
 - a. In witnessed bradycardia or unresponsiveness, quickly increase the energy level to maximum milliamps until electrical and mechanical capture, then slowly decrease the energy slightly above the lowest level that provides consistent capture.
 - b. In a conscious patient, slowly increase current to a level slightly more than the threshold for electrical capture.
11. Reassess patient status including level of consciousness, perfusion and vital signs.

Notes:

1. The guidelines shown are manufacturer specific. The step-by-step instructions may vary slightly from one model or manufacturer to another. In every case, follow the manufacturer's instructions for the specific model being utilized.
 2. If pacing leads become disconnected or electrodes loosen, pacer function will cease and pacer energy will decrease to zero.
 3. If ventricular fibrillation occurs, defibrillate immediately. Pacer function will cease when the "Charge" selector is used. Pacer energy will decrease to zero (pacing rate will decrease to 40 bpm) after defibrillation.
 4. To electively terminate pacing, press "Start/Stop" selector.
 5. When pacing is successful, document rate paced, energy used and positive capture on PaPCR. If pacing is unsuccessful, documentation is to include a statement that external pacing was attempted.
 6. If ECG size is too low, pacer will operate asynchronously and may result in ventricular fibrillation.
 7. Assess that pacer is sensing and marking the QRS complex and not the T-wave. If the T-wave is marked, change either the lead select or electrode placement to establish QRS sensing. Discharge on the T-wave will result in ventricular fibrillation.
 8. Skeletal/muscle twitching should be expected. It is not an indication of pacer capture. If the patient is in discomfort, consider sedation
-